

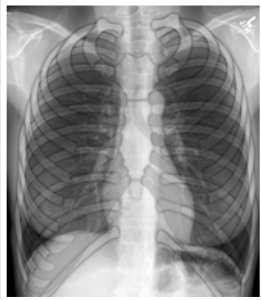
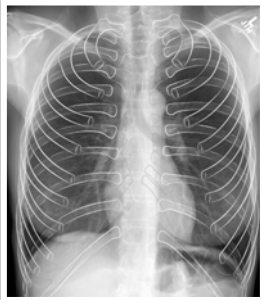
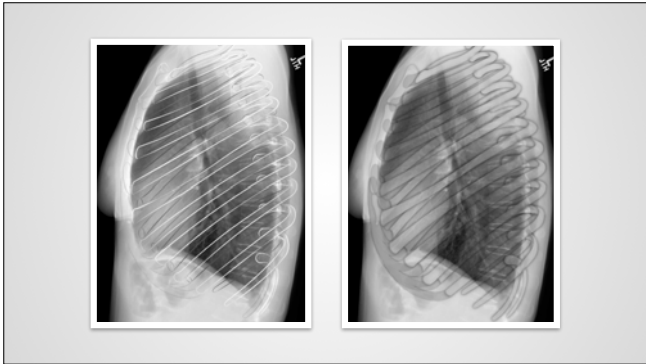
The pleura, diaphragms, and chest wall

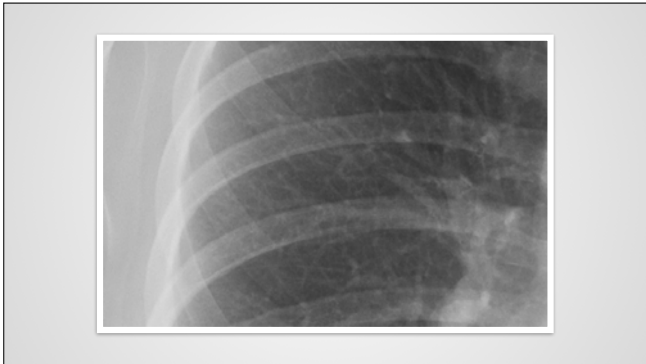
The chest wall—radiological anatomy (rAnatomy)

What will I gain from this video?

After watching this video, you will know how to identify the soft tissue and bones of the chest wall.

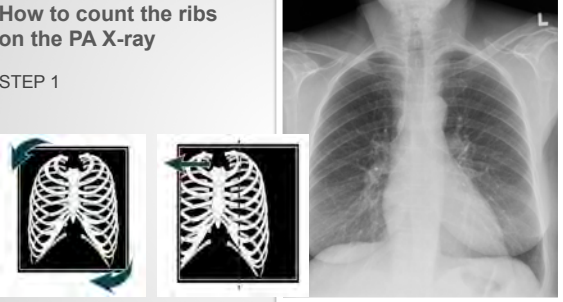






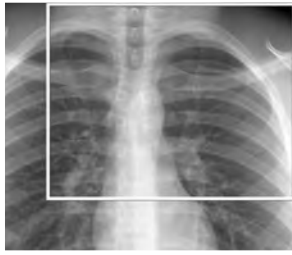How to count the ribs on the PA X-ray

STEP 1



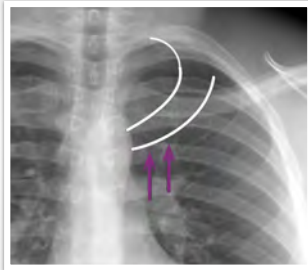
**How to count the ribs
on the PA X-ray**

STEP 2



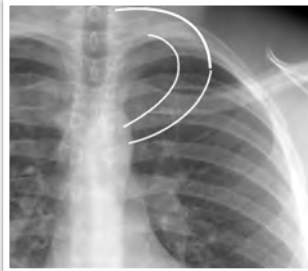
**How to count the ribs
on the PA X-ray**

STEP 3



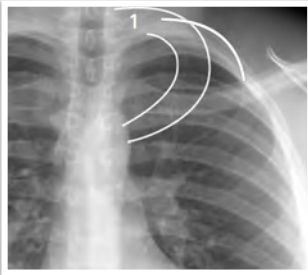
**How to count the ribs
on the PA X-ray**

STEP 4



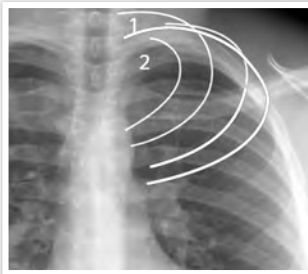
**How to count the ribs
on the PA X-ray**

STEP 5



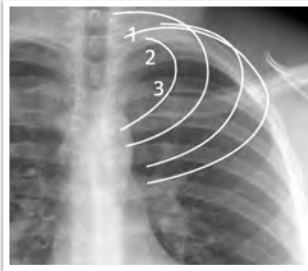
**How to count the ribs
on the PA X-ray**

STEP 6



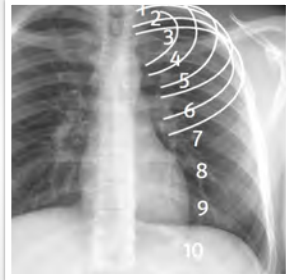
**How to count the ribs
on the PA X-ray**

STEP 7

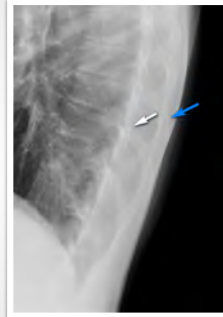

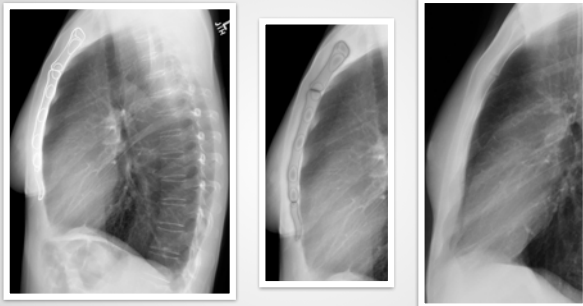
How to count the ribs
on the PA X-ray

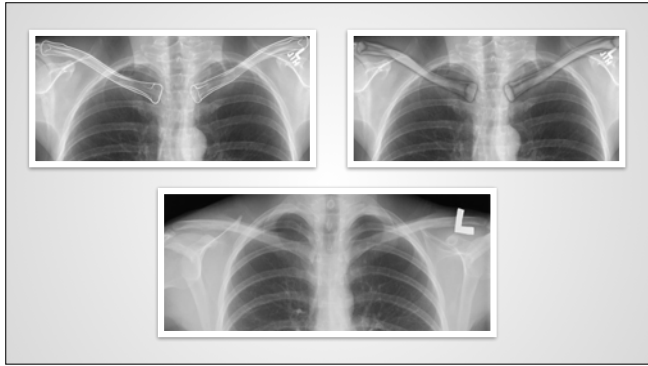
STEP 8

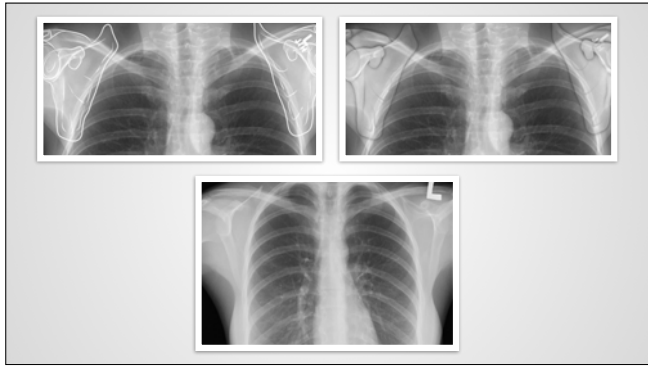


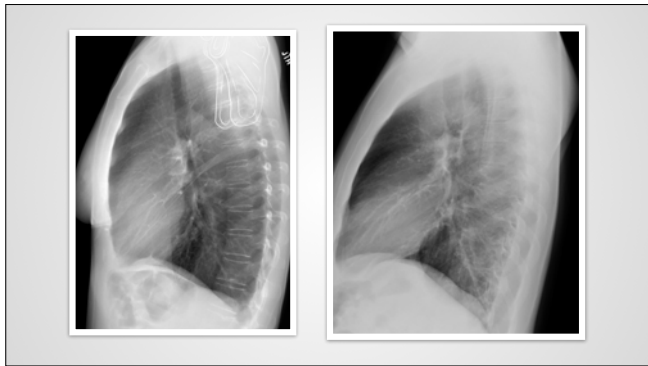
Lateral left and right

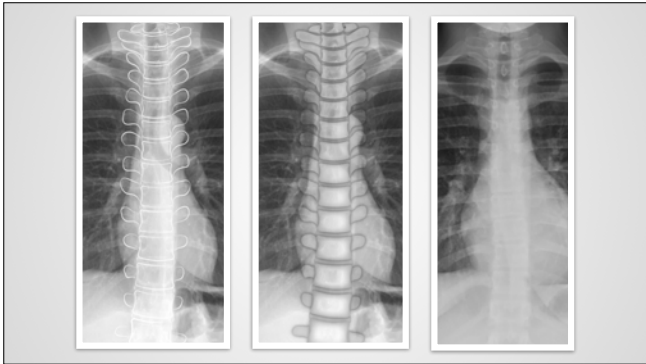


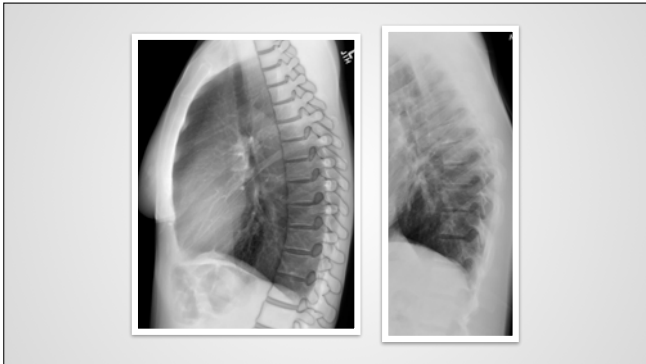


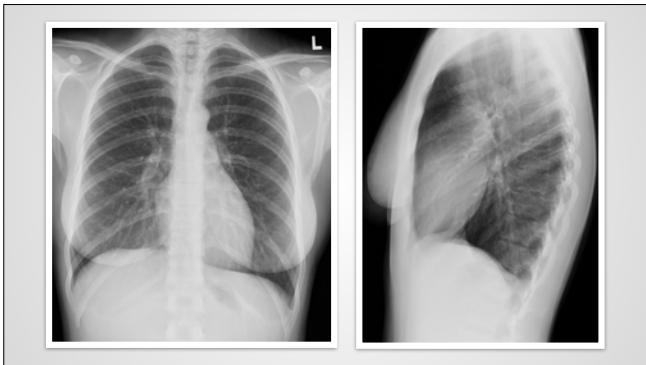


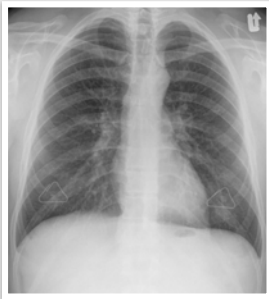










Chest wall evaluation requires specific focus and concentration.

Chest wall evaluation requires specific focus and concentration.

Use a magnifying glass.

Chest wall evaluation requires specific focus and concentration.

Use a magnifying glass.

Compare side to side.

Chest wall evaluation requires specific focus and concentration.

Use a magnifying glass.

Compare side to side.

Ribs and clavicles can obscure pathology in the apices.

Chest wall evaluation requires specific focus and concentration.

Use a magnifying glass.

Compare side to side.

Ribs and clavicles can obscure pathology in the apices.

Medial borders of the scapula can mimic pneumothorax.
